



DR
Paws

ID	:		Ref.by	:	Dr. Paws New Giza
Name	:	Cat Milo of Ms. Jenna Badr	Requested	:	24/1/2026
Age/Sex	:	5 Years/	Reported	:	24/1/2026

Cytology Report

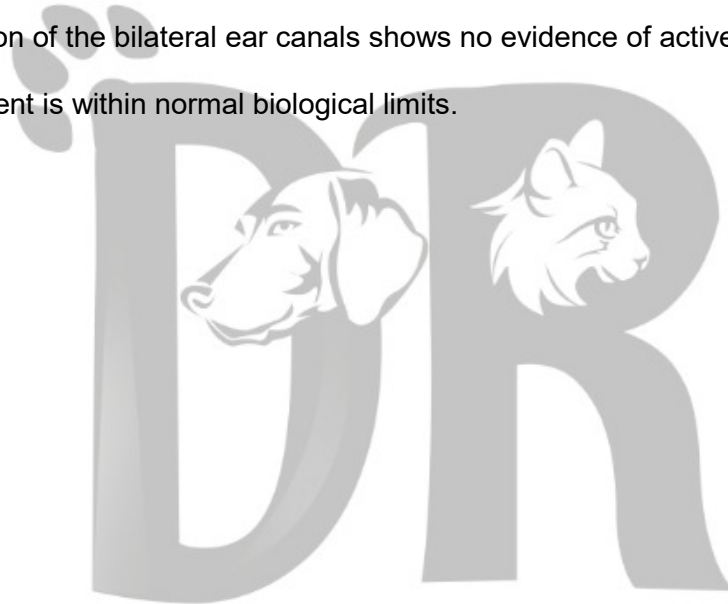
Specimen Characteristics

Ear Cytology

Microscopic Examination

The cytological evaluation of the bilateral ear canals shows no evidence of active infection or parasitic infestation.

The microbial flora present is within normal biological limits.



01008886446



Ahmed_brkat@windowlive.com



www.dr-paws.com



التجمع الخامس - البنفسج 7 - صنية الرطاب مقابل الدخان - فيلا 212