

DR. Paws Hospital

Animal Owner:CHRISTELLE CLARES

Animal Name:GISMO

Species:Canine(<5kg)

Animal ID:20251125-200009-9C54

Gender:Neutered Male

New Cairo Branch

Telephone:01008886446

Medical Director:Dr. Ahmed Barakat



Exam Date:25/11/2025

Equipment Used:Mindray Vetus 50

Operator:

Cardiology - 1/3 Page

2D Measurements

Aorta & Aortic Valve

LA/Ao(2D)

LA Diam: 2.06cm; Ao(LA) Diam: 1.03cm; LA/Ao: 2.00

Doppler Measurements

MV

MV E Vel: 248.28cm/s; MV E PG: 24.66mmHg; MV A Vel: 39.44cm/s; MV A PG: 0.62mmHg; MV E/A: 6.30

AR

AR Vmax: 85.96cm/s; AR PGmax: 2.96mmHg

TV

TV E Vel: 43.15cm/s; TV E PG: 0.74mmHg; TV A Vel: 34.16cm/s; TV A PG: 0.47mmHg; TV E/A: 1.26

Pulmonary Valve

PV

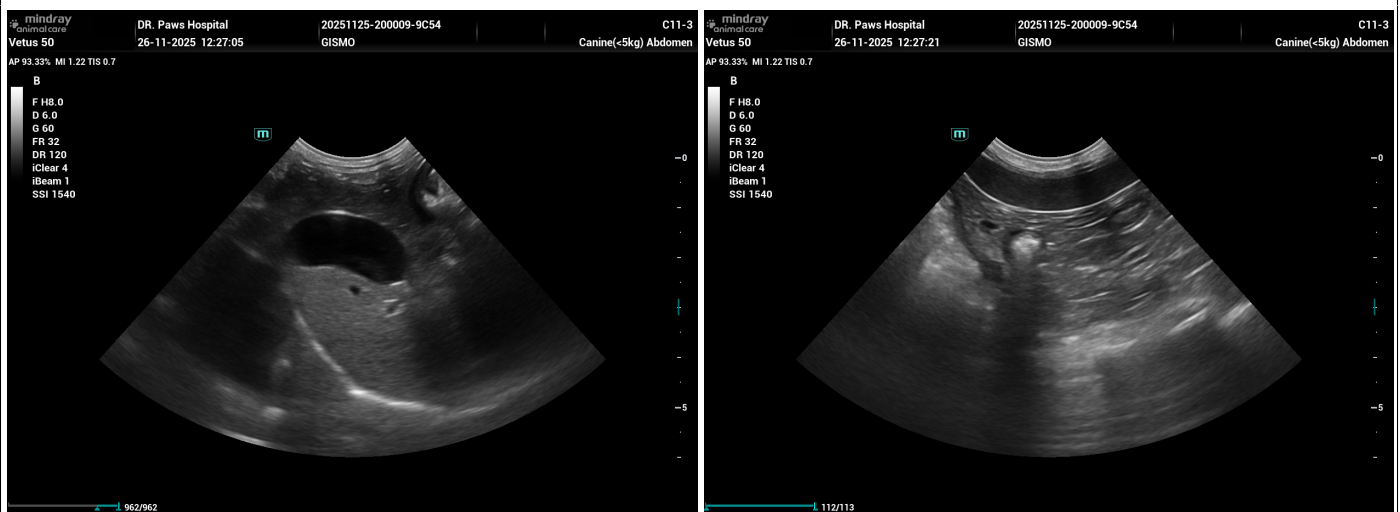
PV Vmax: 68.76cm/s; PV PGmax: 1.89mmHg

PISA

PISA AR

AR Vmax: 85.96cm/s

Ultrasound Image

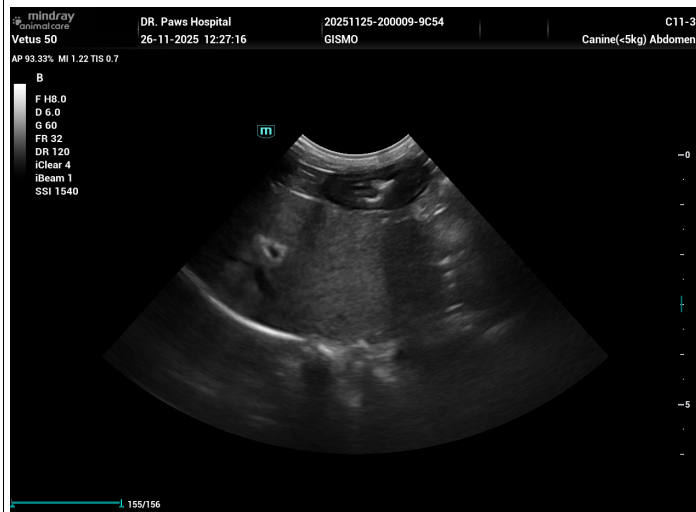
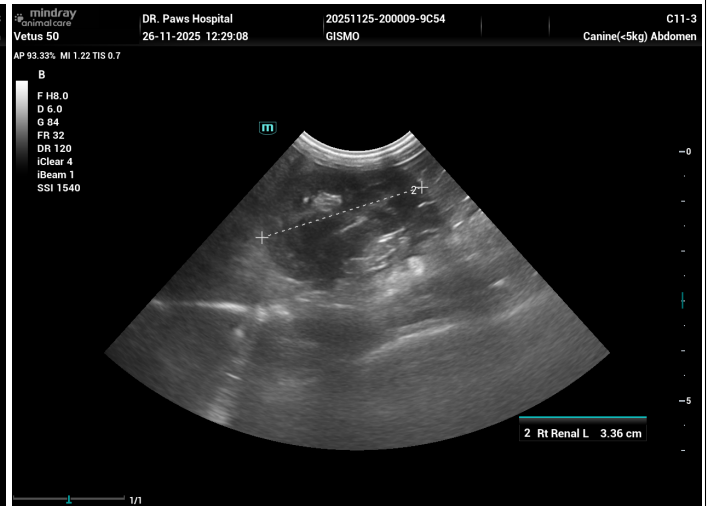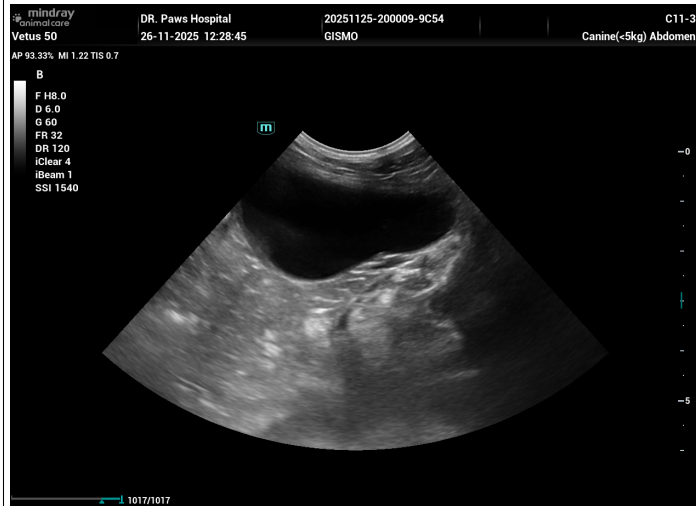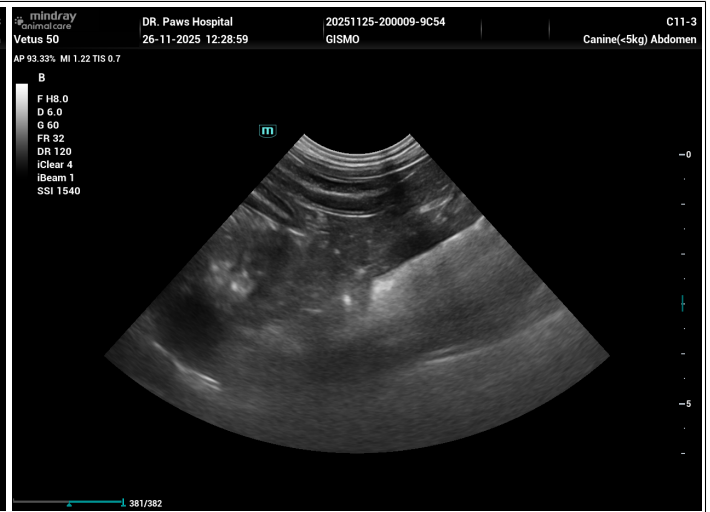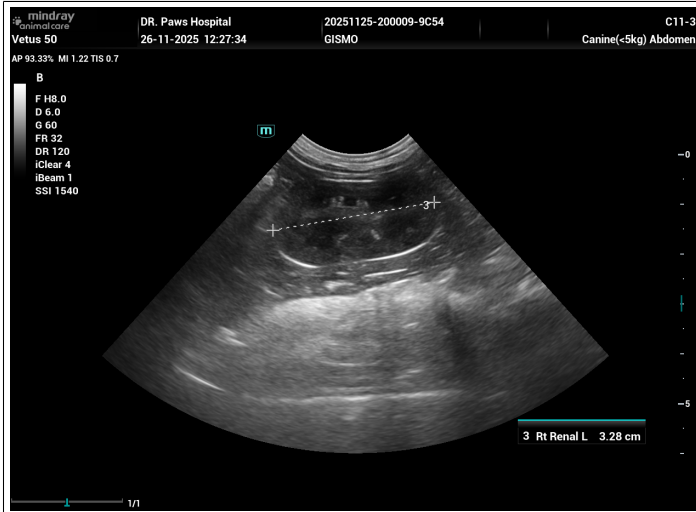




Animal Name:GISMO Animal ID:20251125-200009-9C54

Exam Date:25/11/2025

Cardiology - 2/3 Page





Animal Name:GISMO **Animal ID:**20251125-200009-9C54

Exam Date:25/11/2025

Cardiology - 3/3 Page

Comments:

Findings:

Thickening OF MITRAL VALVE LEAFLET INDICATING MMVD

MILD TO MODERATE Mitral REGURGIATION MV E Vel 248.28cm/s

Normal TV TV E Vel 43.15cm/s TV A Vel 34.16cm/s FLOW

NORMAL PV Vmax 68.76cm/s FLOW

NORMAL AV FLOW AR Vmax 85.96cm/s

ELEVATED LA Diam 2.06.cm

ELEVATED LA/Ao 2

NORMAL FS% 48 %

Diagnosis:

Mmvd STAGE B1

Signature(seal):

Date Signed: