



Dr Paws Animal Hospital

Address: Egypt, New Cairo

+201008886446/+201117873666

Paws Dr.paws.egy@gmail.com

-Medical Report-

Patient: Mia

Species: canine

Breed: toy poodle

Date of Birth: 31/10/2025

Body weight: 1.8kg

Owner name: Rana Olabi

Microchip number : 900233006365975



• Case History:

According to the owner, the dog fell from a chair at home on Tuesday 17/2/2026 .
Following the fall, the dog showed pain, swelling, and inability to bear weight on
both forelimbs

• Physical Exam & Diagnosis:

X-ray show Bilateral mid-shaft fractures of the radius and ulna.

Laboratory Results:

Pre-operative blood work performed using IDEXX Laboratories showed all parameters
within normal reference ranges.

Physical Examination:

Physical examination parameters were within normal limits. Vital signs including
temperature, pulse, and respiration were normal. Mucous membranes were pink with
normal capillary refill time.

Pre-Anesthetic Assessment:

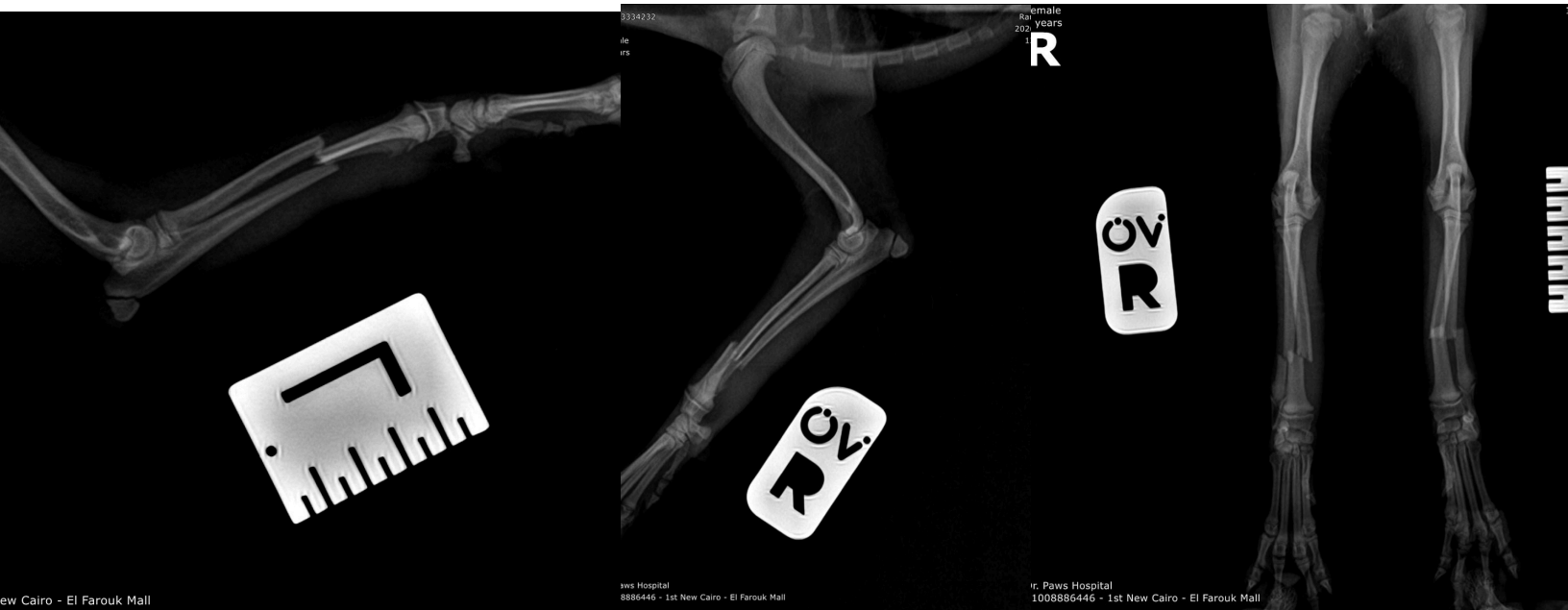The patient was classified as ASA I (normal healthy patient with no systemic disease).

Surgical Procedures:

Left forelimb fracture fixation was performed using bone plate fixation with Intrauma
Vet System on Tuesday, 17 February 2026.

Right forelimb fracture fixation was performed using bone plate fixation with Arthrex
Vet Systems on Thursday, 19 February 2026.

Diagnostic Image



X-ray show Bilateral forelimb Radius & Ulna Fracture

Chemistry

17/2/2026 2:26 pm

TEST	RESULT	REFERENCE VALUE	
Glucose	140	77 - 150 mg/dL	<input type="text"/>
Creatinine	0.9	0.3 - 1.2 mg/dL	<input type="text"/>
Urea	29	7 - 29 mg/dL	<input type="text"/>
BUN: Creatinine Ratio	34		
Phosphorus	7.3	5.1 - 10.4 mg/dL	<input type="text"/>
Calcium	10.7	7.8 - 12.6 mg/dL	<input type="text"/>
Total Protein	5.6	4.8 - 7.2 g/dL	<input type="text"/>
Albumin	3.1	2.1 - 3.6 g/dL	<input type="text"/>
Globulin	2.6	2.3 - 3.8 g/dL	<input type="text"/>

Generated by VetConnect® PLUS 17 February, 2026 © 2025 IDEXX Laboratories, Inc. All rights reserved. US D1072841 S.

IDEXX

MIA OLABI

PET OWNER: RANA OLABI
 SPECIES: Canine
 BREED: Poodle
 GENDER: Female Entire
 AGE: 3 Months
 PATIENT ID:

Dr. Paws Hospital
 1st Settlement, New Cairo., Al Farouk Mall, Al Banafsag 10
 Cairo, Egypt 11865
 +201008886446 /+2011 17873666
 ACCOUNT #:
 ATTENDING VET: Nadia Essam

IDEXX Services: IDEXX VetAutoread Haematology Analyser, Catalyst One Chemistry Analyser

Haematology

17/2/2026 2:25 pm

TEST	RESULT	REFERENCE VALUE	
Haematocrit	38.8	37.0 - 55.0 %	<input type="text"/>
Haemoglobin	13.1	12.0 - 18.0 g/dL	<input type="text"/>
MCHC	33.8	30.0 - 36.9 g/dL	<input type="text"/>
% Reticulocytes	~0.9	%	
WBC	9.80	6.00 - 16.90 K/ μ L	<input type="text"/>
% Granulocytes	54.1	%	
% Lym and Mono	46	%	
Granulocytes	5.30	3.30 - 12.00 K/ μ L	<input type="text"/>
Lym and Mono	4.5	1.1 - 6.3 x10 ⁹ /L	<input type="text"/>
Platelets	317	175 - 500 K/ μ L	<input type="text"/>

These are ADULT hematology reference ranges.

IDEXX

MIA OLABI

PET OWNER: RANA OLABI

DATE OF RESULT: 17/2/2026

LAB ID:

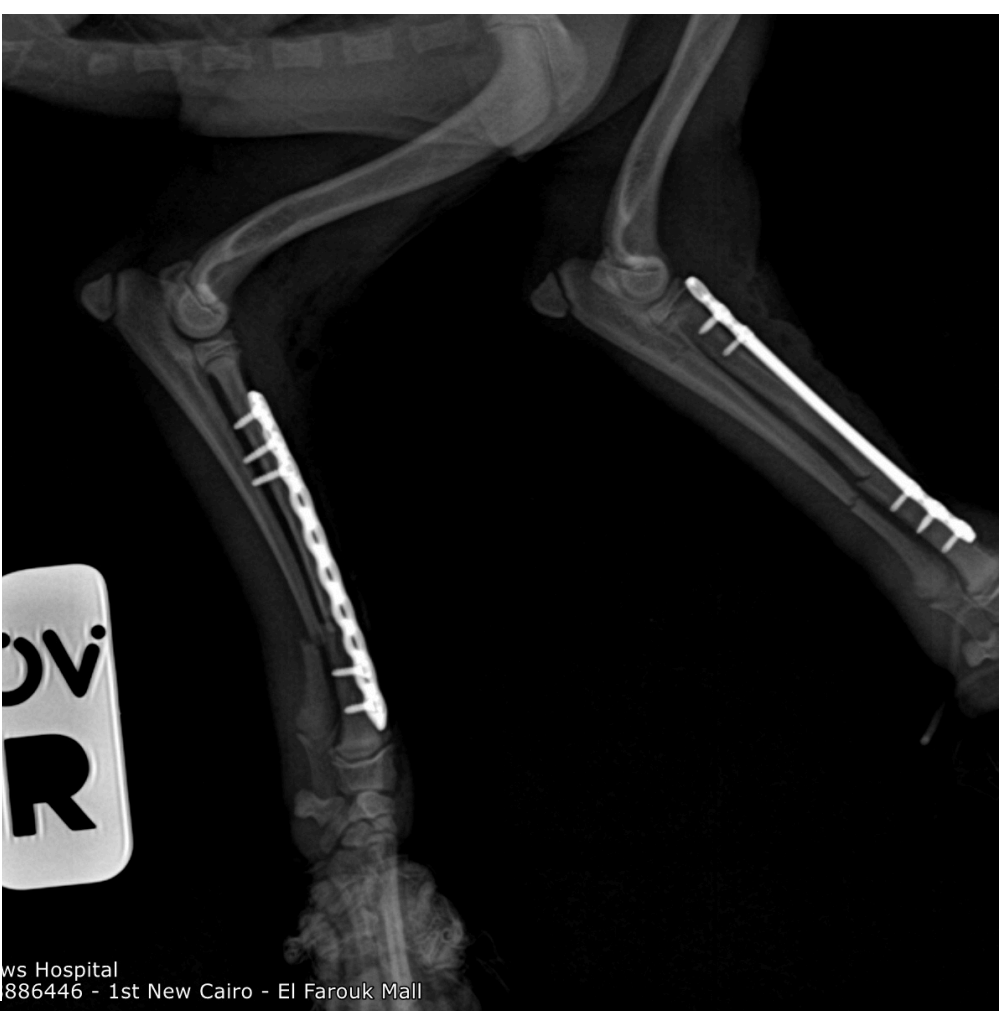Chemistry (continued)

TEST	RESULT	REFERENCE VALUE	
Albumin: Globulin Ratio	1.2		
ALT	74	8 - 75 U/L	<input type="text"/>
ALP	137	46 - 337 U/L	<input type="text"/>
GGT	2	0 - 2 U/L	<input type="text"/>
Bilirubin - Total	<0.1	0.0 - 0.8 mg/dL	<input type="text"/>
Cholesterol	200	100 - 400 mg/dL	<input type="text"/>
Amylase	487	300 - 1,300 U/L	<input type="text"/>
Lipase	441	100 - 1,500 U/L	<input type="text"/>

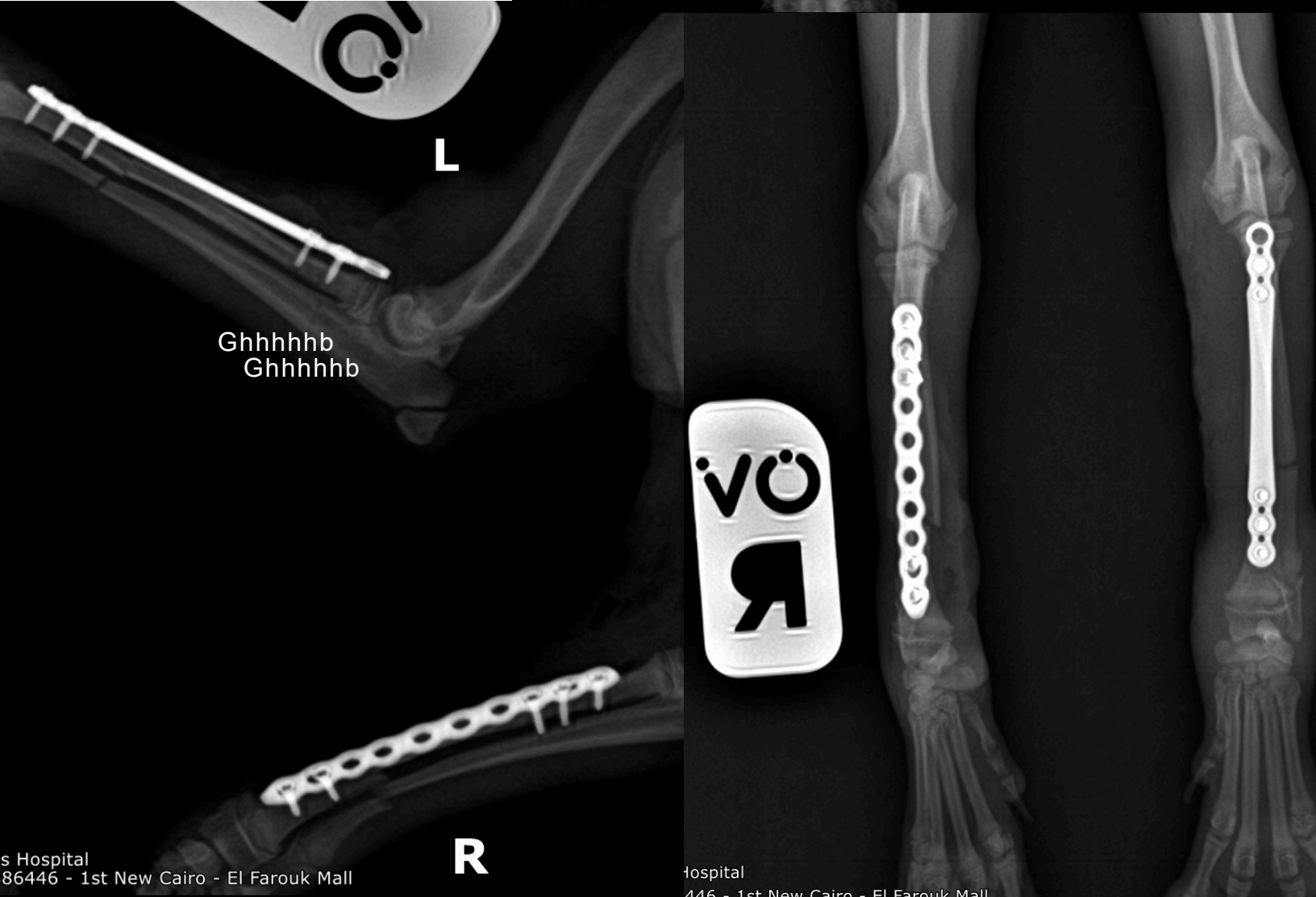
Pre-operative Blood work test

Post-Operative x-ray Left forelimb fracture fixation was performed using bone plate fixation with Intrauma Vet System on Tuesday, 17 February 2026.

Right forelimb fracture fixation was performed using bone plate fixation with Arthrex Vet Systems on Thursday, 19 February 2026.



... Hospital
836446 - 1st New Cairo - El Farouk Mall



Ghhhhb
Ghhhhb

s Hospital
86446 - 1st New Cairo - El Farouk Mall

ospital
446 - 1st New Cairo - El Farouk Mall

Post-Operative care and medication (Oral)

To be continued for 10- 14 days, and may be adjusted depending on wound healing status and clinical progress.

Dual antibiotic therapy (oral):

Cephalexin: 40 mg/kg PO BID

Clindamycin: 20 mg/kg PO BID

Oral anti-inflammatory drug (as prescribed).

Oral bone support supplements:

Omega-3 fatty acids

Glucosamine

Chondroitin

Calcium supplements

Prognosis and follow up

The overall prognosis for the patient is good. Close monitoring is required for the operated limbs, including wound healing and bone union.

Radiographic follow-up is recommended every three weeks to monitor fracture healing and implant position.

In some cases, due to limited blood supply to the bone specially in toy breed dogs, the plate and screws may cause a local reaction, which could necessitate implant removal.

Client Education and Post-Operative Instructions:


The owner has been fully informed of all possible complications, including infection, delayed bone healing, implant-related reactions, and the potential need for implant removal.

The owner has been instructed to prevent the dog from licking or chewing the surgical wounds.

Strict cage rest is recommended until complete bone healing is confirmed. Regular rechecks and radiographs are essential to ensure proper recovery.



VACCINATION RECORD



Anti-viral Vaccination

VACCINATION	Batch/Lote	Date Given	Next Date
Nobivac DHPPI	A838A01	25 Jan 2026	15 Feb 2026
Nobivac Lepto	A488A01		
Nobivac DHPPI	A838A01	17 Feb 2026	3 March 2026
Nobivac Lepto	A492A01		
Nobivac Rabies	A780A02	14 Jan 2026	14 Jan 2027
Nobivac Rabies	A782B01	17 Feb 2026	17 Feb 2027
Simparica Trio	Deworming & Antiflea	21 Feb 2026	21 March 2026



Sincerely

Dvm. NADIA Essam

Dr Paws Animal Hospital

22 February 2026