



Paws

ID	:	Ref.by	:	Dr.Paws
Name	:	Requested	:	6/1/2025
Age/Sex	:	Reported	:	13/1/2025

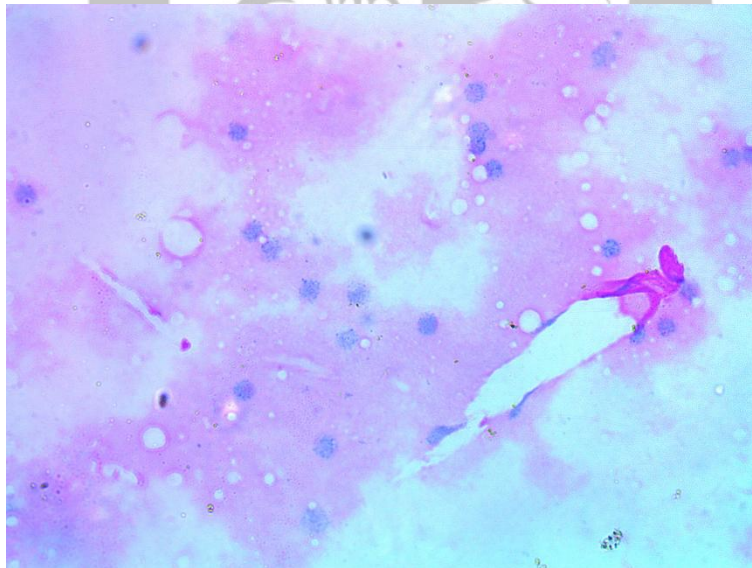
## Cytologicalreport

### Specimen Characteristics

Fluid

### Microscopic Examination

Microscopic examination: showing high number of inflammatory cells mainly



Diagnosis : Infammation with no signs of malignancy

Pathologist: Dr. Islam Elgohary

Researcher of Pathology, AHRI



01008886446



Ahmed\_brkat@windowlive.com



www.dr-paws.com



التجمع الخامس - البنفسج 7 - صنية الرطب مقابل الدخان - فيلا 212