



DR. Michael Heshmat Vet Cardiologist & Acupuncturist

01550250322

Electrocardiogram

Identification

Identification: ---	Date: 10/01/2026 02:32:28	Weight: 6.2 kg
Patient: toffy	Age: 6 Years and 11 Months	Gender: Male
Species: Dog	Breed: Shih tzu	
Owner: ---	Requester: DR.PAWS (main)	

Observed Parameters

P duration: 42 ms	ST segment: 30 ms	T amplitude: 0.56 mV
QRS duration: 64 ms	P amplitude: -0.43 mV	P Axis: -99.68 °
T duration: 88 ms	R amplitude: -0.51 mV	QRS axis: -76.69 °
QT interval: 182 ms	S amplitude: -0.08 mV	Mean HR: 282 bpm

Comments

Low amplitude R wave and high amplitude and duration of T wave

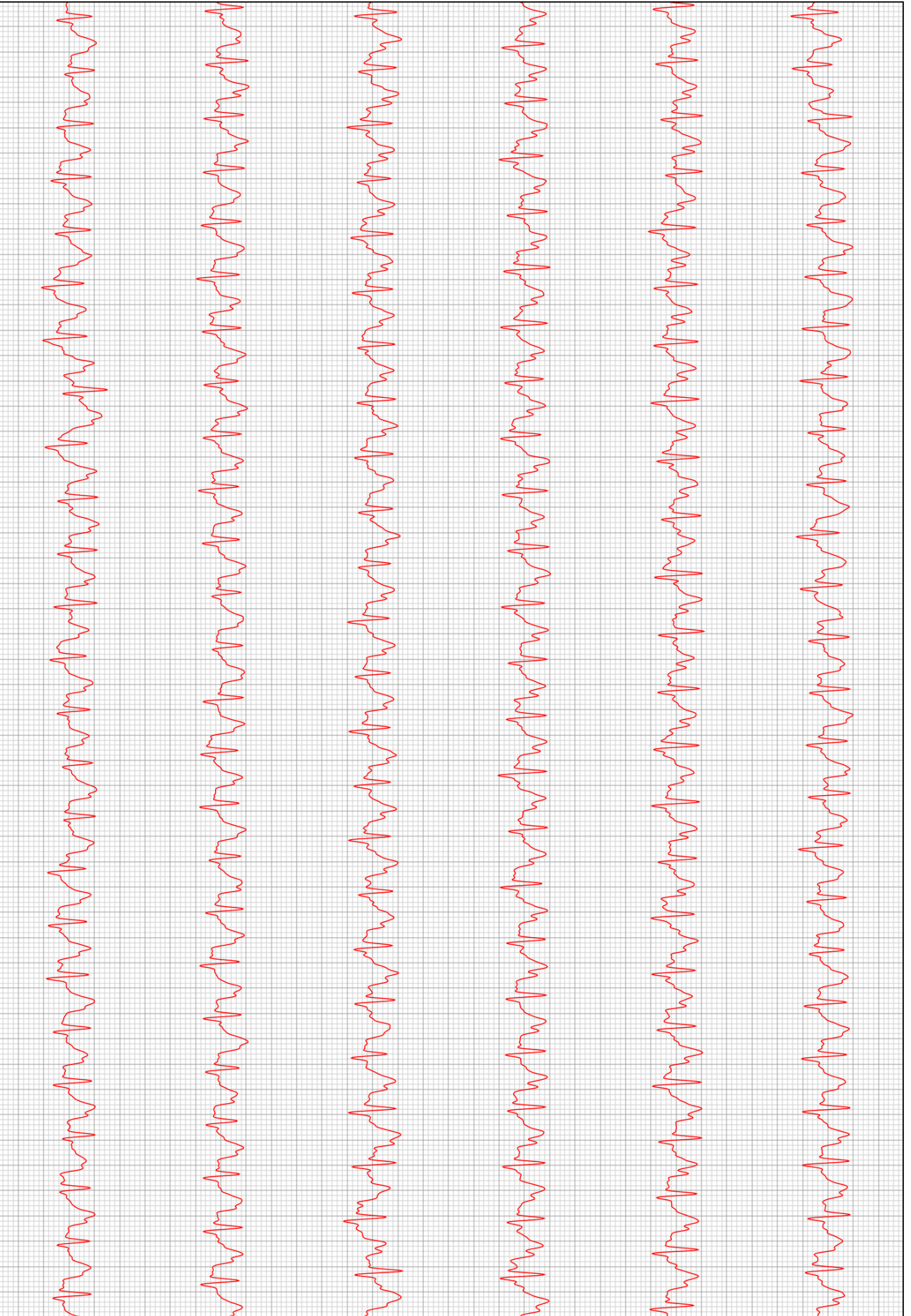
Conclusions

Sinus tachycardia



DR.Michael Heshmat

Electronically signed by:



D2

