



Eslam Hendy (DVM, MSc. Oral And Dental Surgery)

FACULTY OF VETERINARY MEDICINE,
ZAGAZIG UNIVERSITY (Egypt)

Phone: 01060885731
e-mail: eslam.hendy23@gmail.com

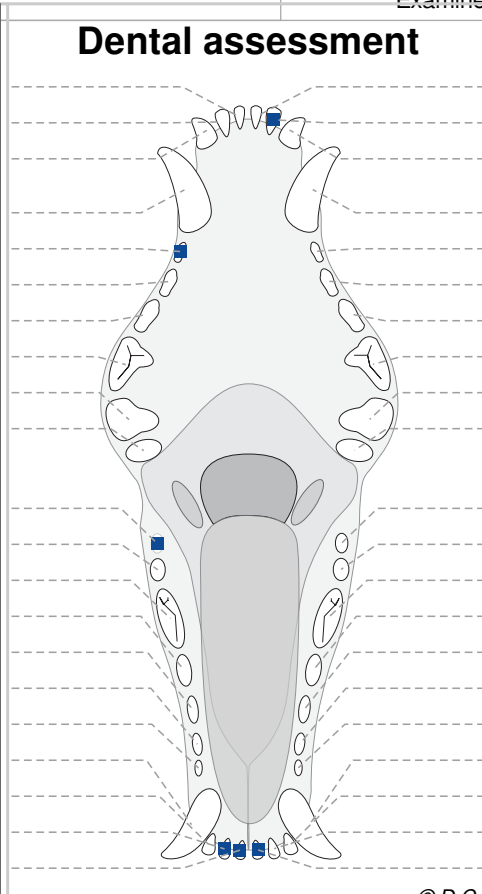
Date: 28/09/2025

Patient name: Fluffy

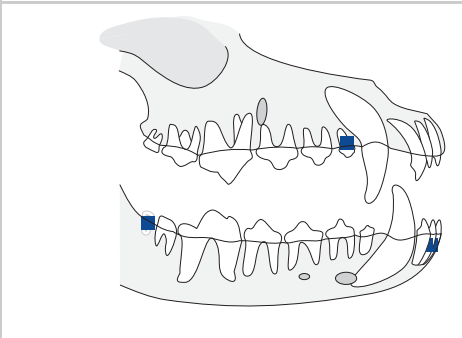
Client: Mrs. Elhamy Doha

Examiner: **ESLAM HENDY**

I	M	F	P	E	
					101 (I1)
					102 (I2)
					103 (I3)
					104 (C)
					105 (P1)
					106 (P2)
					107 (P3)
					108 (P4)
					109 (M1)
					110 (M2)
Right					
	●				411 (M3)
					410 (M2)
					409 (M1)
					408 (P4)
					407 (P3)
					406 (P2)
					405 (P1)
					404 (C)
					403 (I3)
					402 (I2)
					401 (I1)

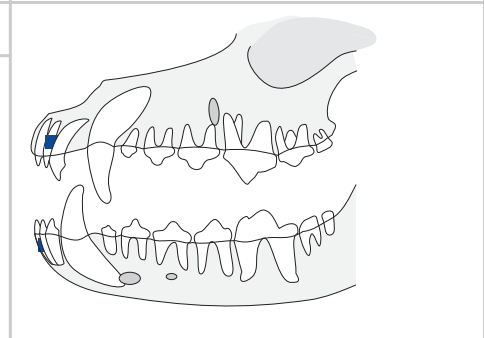


	I	M	F	P	E	
						201 (I1)
						202 (I2)
						203 (I3)
						204 (C)
						205 (P1)
						206 (P2)
						207 (P3)
						208 (P4)
						209 (M1)
						210 (M2)
Left						
						311 (M3)
						310 (M2)
						309 (M1)
						308 (P4)
						307 (P3)
						306 (P2)
						305 (P1)
						304 (C)
						303 (I3)
						302 (I2)
						301 (I1)



Legend

- I Inflammation index (1-4)
- M Missing tooth
- F Fractured tooth
- P Persistent deciduous tooth
- E Extraction



Occlusion: Mandibular distocclusion (class 2)
Calculus level: ++

General Notes:
Dental Scaling and Root Planning
Endodontic TTT
Follow up the lower incisors

- Notes:**
- 105 (P1): Wide Pulp
 - 202 (I2): Wide Pulp, periapical lucency
 - 301 (I1): Mobile tooth -Bone resorption
 - 401 (I1): Mobile tooth -Bone resorption
 - 402 (I2): Mobile tooth -Bone resorption
 - 411 (M3): Missing- Absent on x rays



