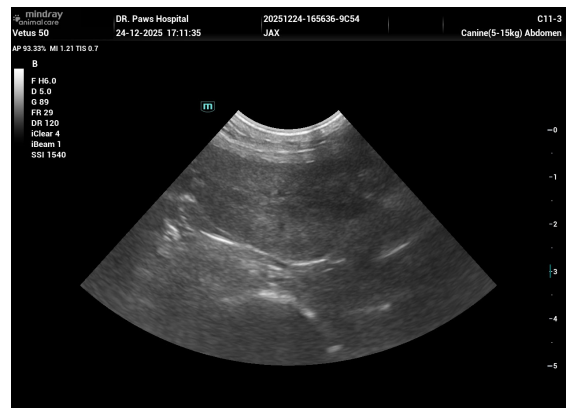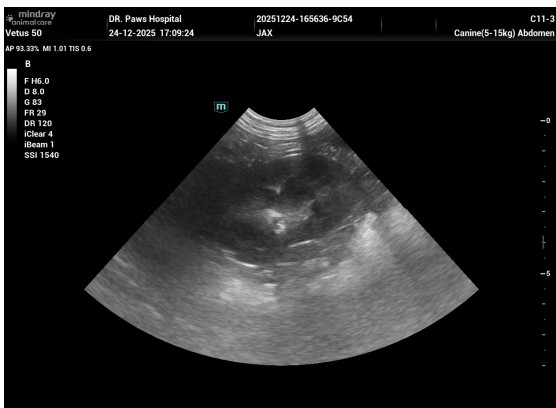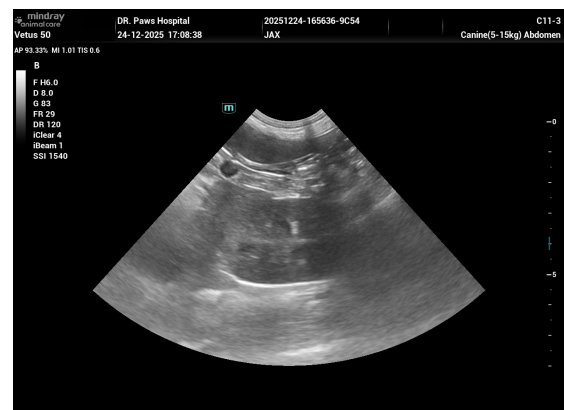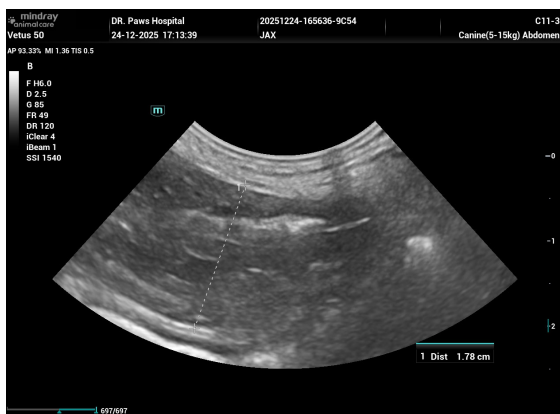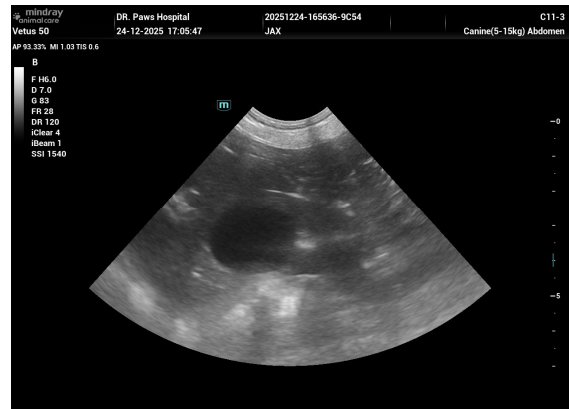
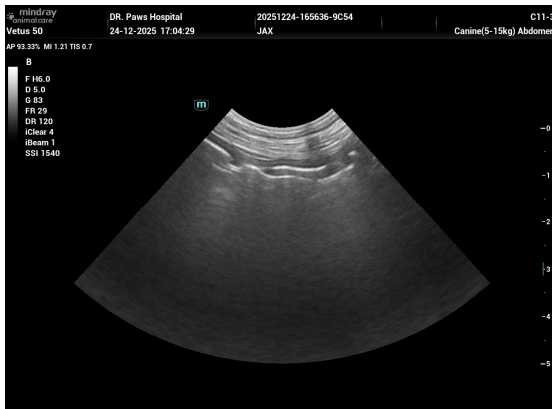
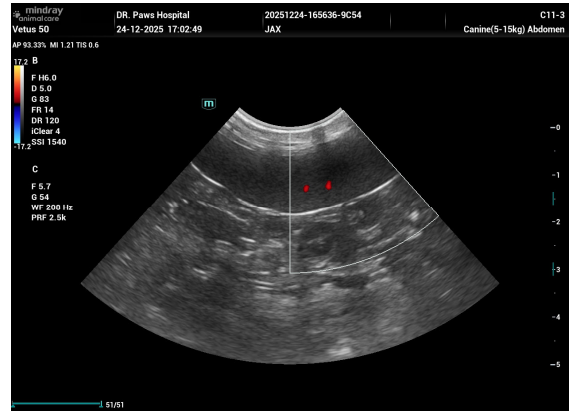




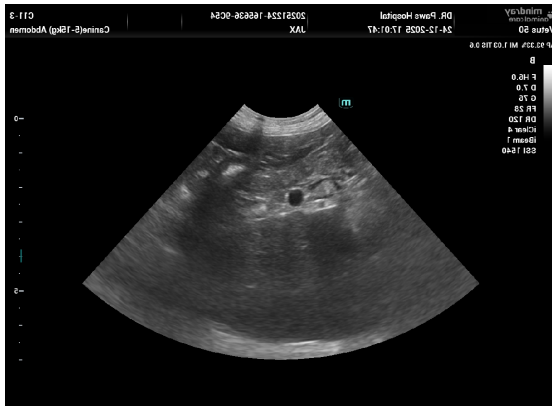Abdomen





Findings:

- Severe thickening in the gastric wall measured 7mm, Hugely distended with gases forming artifact.
- Dilated descending colon lumen measured 1.7mm, edematous mucosal layer.
- Hypoechoic focal lesions scattered on splenic parenchyma.
- Increase in the pancreas size with granular appearance.
- Distended GB with bile which's normal in fasting state.
- Increase in Prostate dimensions measured 6.5*2.

Diagnosis:

- **Gastroenteritis** represented as: Severe gastritis, Moderate pancreatitis, Dilated descending colon is suggestive for colonic inertia.
- Incidental Finding: **Benign prostatic hyperplasia.**

Comments:

- **Gastric coating and protectants** 30min before meals at the morning in daily basis for 1mnth.
- **Probiotics** to balance the intestinal flora after the huge destruction occurred as a result of unwise use of the antibiotics.
- Using **immune stimulants** to counteract the side effects of corticosteroid doses used, containing essential minerals and B-cmplx to support the neurons supplying colon and rear limbs it would not only help improve the gait but also improve the peristaltic movement and the intestinal emptying, supplements for 1mnth.
- **Stick to high fiber low fat diet**, gastrointestinal medicated formulations highly recommended especially high fiber formulation as it has great influence on regulating the intestinal emptying time, in addition to containing beneficial *Lactobacillus* spp supporting the intestinal microbiome, it's recommended to supply pure gastrointestinal medicated formulations for 1mnth.
- Adding **psyllium husks** to home made diets, 1tsp on food once daily.
- Repeat the lab works monthly.

Wishing this upcoming new year be free of any illness, to be filled with joy and unforgettable moments with your lovely Jax Insha'allah.

Signature(seal): *Maryam Elhady*

Date Signed: 29th Dec 2025
